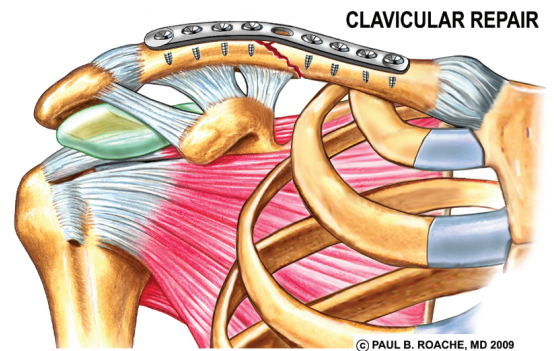
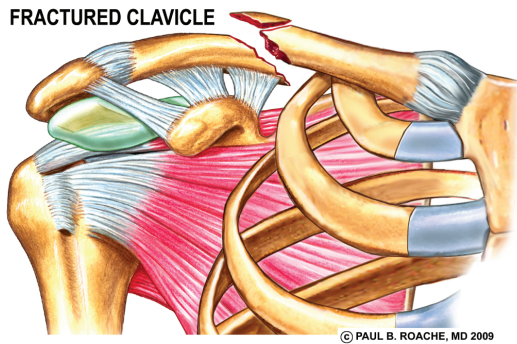
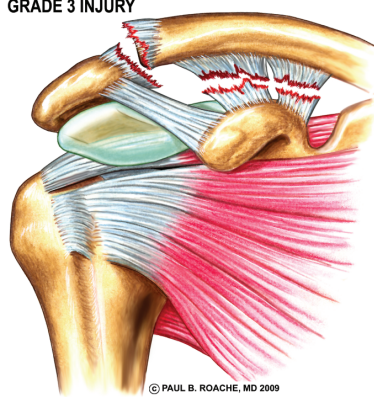
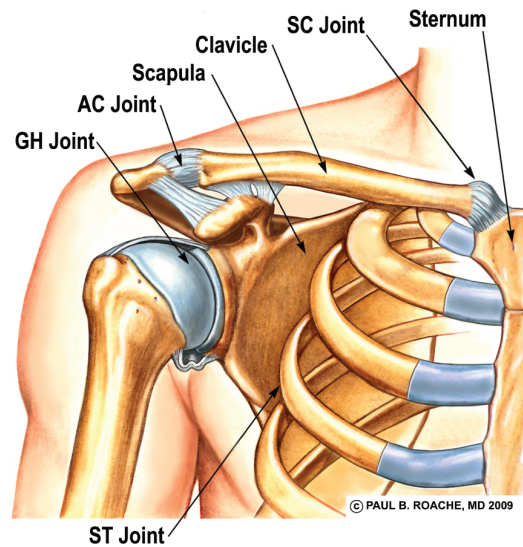
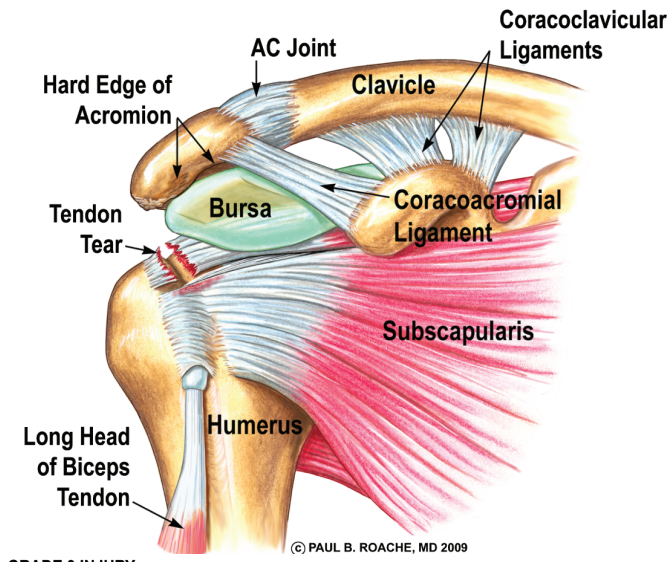
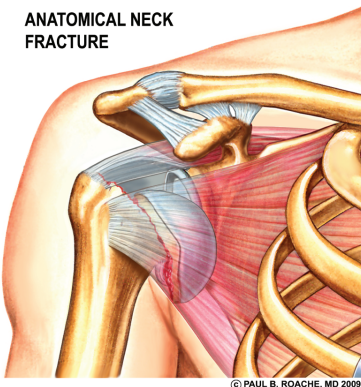


# Clavicle Fractures and AC Joint Injuries

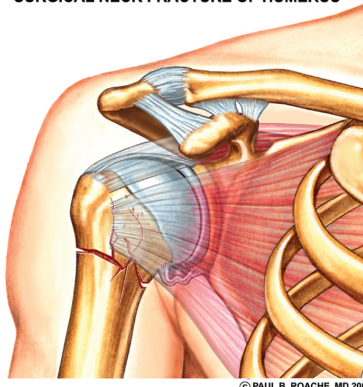


## Fractures of the Ball (Proximal Humerus)

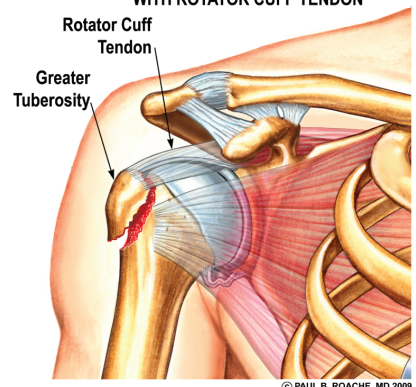
ANATOMICAL NECK FRACTURE



SURGICAL NECK FRACTURE OF HUMERUS



FRACTURED GREATER TUBEROSITY WITH ROTATOR CUFF TENDON



## Cartilage Injury: Arthritis of the Ball-and-Socket

